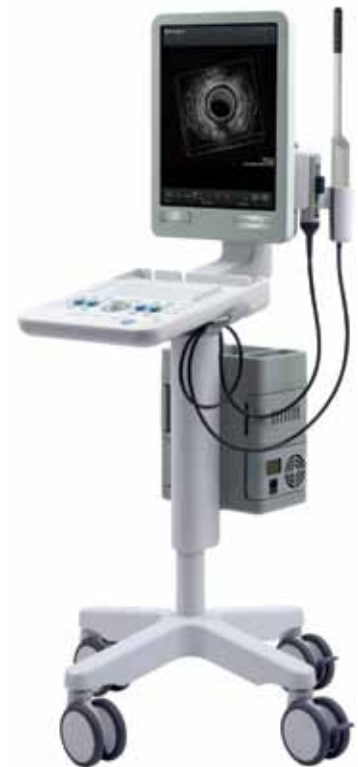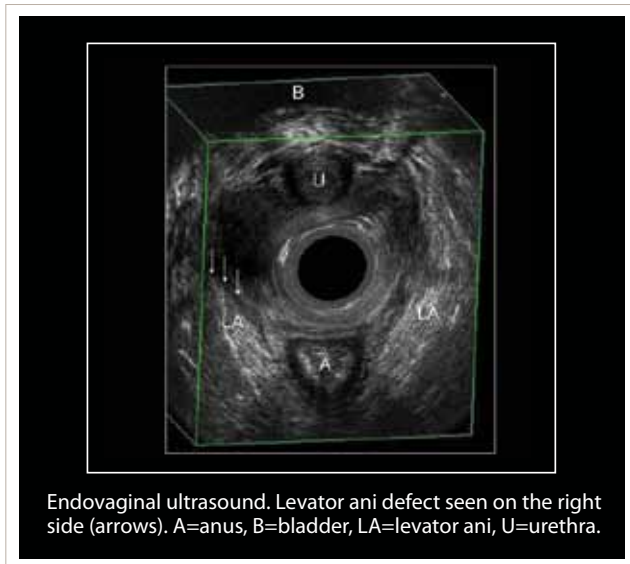




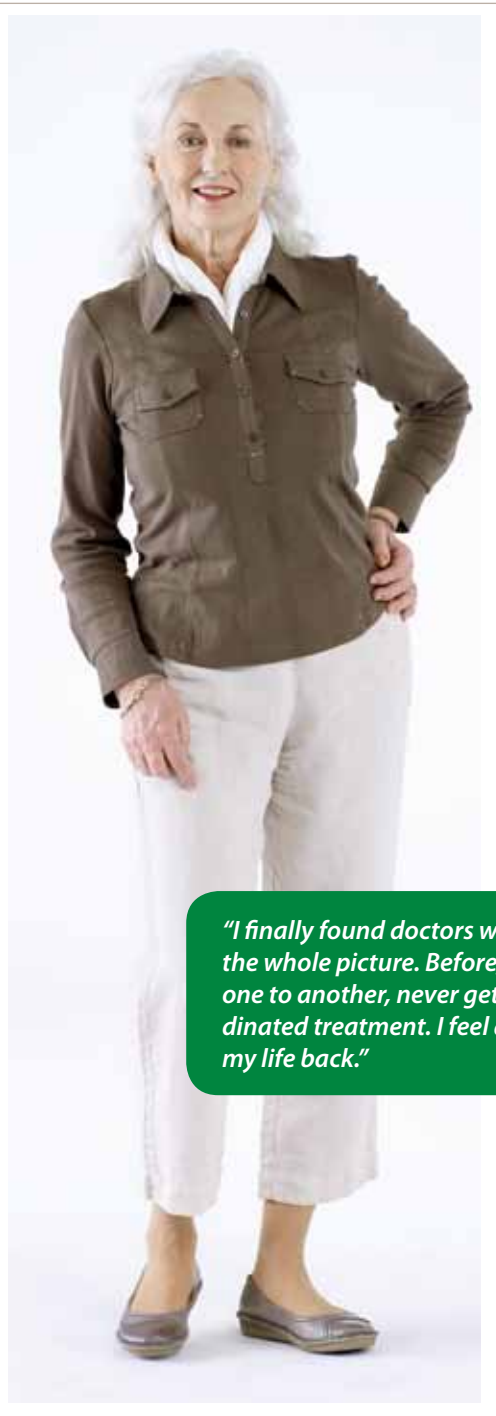## Look Beyond the Surface and Get the Complete Pelvic Floor Picture



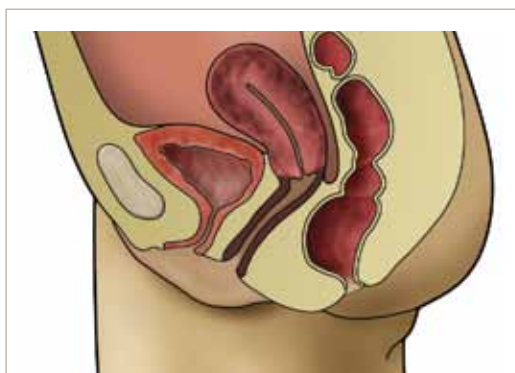### The World Leader in Pelvic Floor Ultrasound Imaging

- Advanced Imaging Technologies for Suberb Image Quality
- Dynamic Real-Time Examination During Squeeze and Valsalva Maneuvers
- Excellent Visualization of Tape and Meshes
- Manipulate 3D Data to See Structural Details in the Best Plane

# BK Medical Is the World Leader in Pelvic Floor Ultrasound



Our unique solutions let you examine structures and defects from all angles, to gain insight into the condition of all parts of the pelvic floor.



*"[The multicompartiment method] allows us to evaluate the patients with pelvic floor dysfunctions in order to decide the most appropriate management and also to assess the results after surgery."*

*Giulio Santoro, MD, PhD (colorectal surgeon)*

*"I finally found doctors who look at the whole picture. Before, I went from one to another, never getting coordinated treatment. I feel as if I've got my life back."*

*"Any physician or practitioner who treats the patient should incorporate pelvic floor ultrasound into the clinical examination before deciding on a plan of treatment."*

*Marianne Starck MD, PhD (colorectal surgeon)*

Visit the pelvic floor section of [bkmed.com](http://bkmed.com) to download clinical notes by different medical specialists, explaining how and why they use the multicompartiment method in their practice, including guidelines for performing a multicompartiment examination. You will also find a list of references to relevant journal articles.

Ultrasound images courtesy of Dr. S. A. Shobeiri, University of Oklahoma Health Sciences Center, USA, Dr. G. A. Santoro, Regional Hospital, Treviso, Italy, and Dr. A. P. Wiczorek, Skubiszewski Medical University of Lublin, Poland. All images obtained on a Pro Focus 2202 UltraView system.

# Get the Complete Story

Pelvic floor structures are complex, so dysfunctions often involve more than one part of the anatomy.

## Getting the full picture can be critical for:

- Finding the causes of dysfunction
- Planning treatment
- Evaluating outcomes

## Why ultrasound?

- Dynamic real-time examination to observe structures during squeeze and Valsalva maneuvers
- Excellent visualization of tape and meshes
- Immediate, definitive results

## What is multicompartment imaging?

Using ultrasound with a combination of transducers to image all compartments of the pelvic floor:

- Anterior (bladder and urethra)
- Middle (vagina and uterus)
- Posterior (rectum and anal canal)

## Why endocavity imaging?

- With high resolution ultrasound, you can see the fine anatomic details of even deep pelvic floor structures

## Why high resolution 3D?

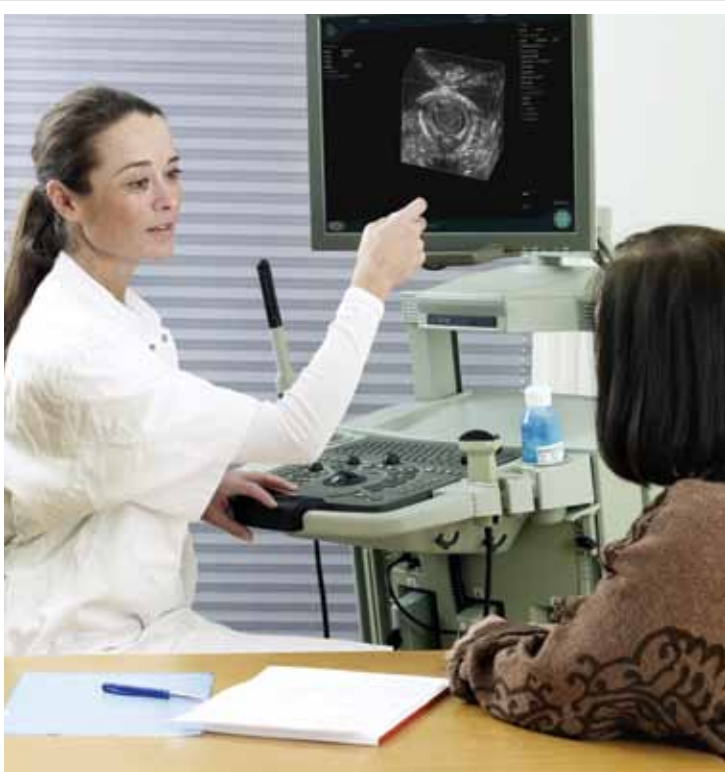- Image, store and compare detailed anatomic information in precise high resolution 3D data cubes
- Manipulate the 3D data to see structural details in the best plane
- Get visual confirmation of precise position of tapes and meshes

## How long does it take?

- Less than 20 minutes, for an experienced physician

## What are some conditions that can be evaluated?

- Pelvic organ prolapse
- Urinary and fecal incontinence, obstructed defecation
- Voiding dysfunction
- Pelvic, vaginal, or anal pain
- Recurrent urinary tract infections
- Pelvic floor dyssynergy



*“There’s a real-time nature to the interaction with the patient... With ultrasound imaging, we can confirm the diagnosis at the initial visit, choose the surgical date and discuss treatment, all in the same day.”*

*Elizabeth R. Mueller MD, MS, FACS (urogynecologist)*

## Quick and Easy Transperineal Overview

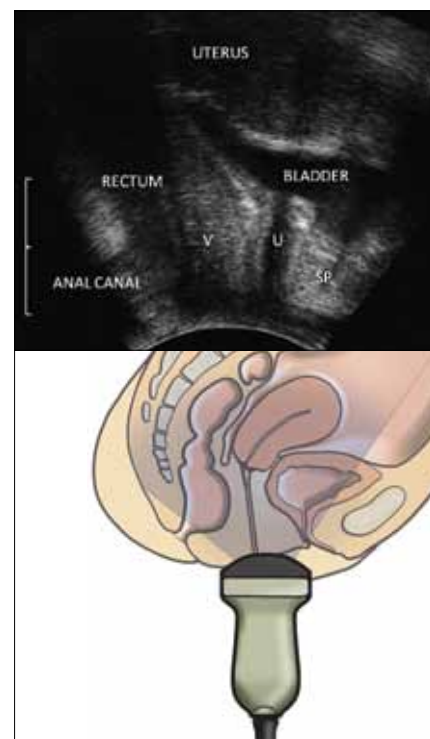
Transperineal ultrasound imaging with the excellent penetration and contrast resolution of the 8802 convex array transducer gives a comprehensive overview of the pelvic floor anatomy and lets you make initial measurements of anatomic structures.

### Use a sagittal view to visualize:

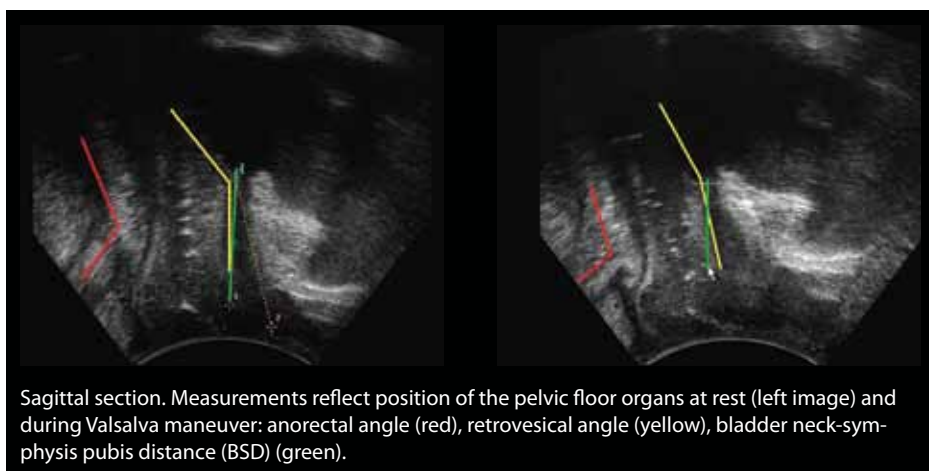
- Urethral hypermobility
- Cystoceles, rectoceles, enteroceles
- Obstructed defecation
- Tapes and mesh
- Bladder neck descent
- Dyskinesia

### Rotate the transducer to the transverse plane to visualize:

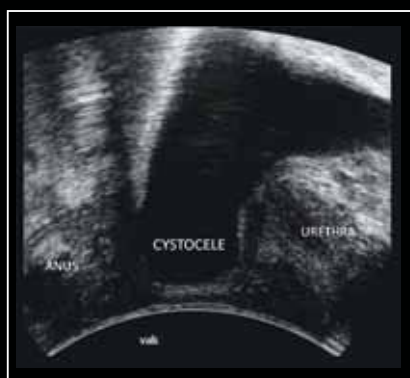
- Sphincter abnormality or urethral rotation



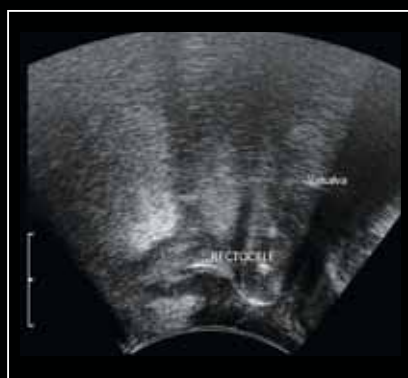
Pelvic floor – normal anatomy in nulliparous patient. Sagittal section, 8802 transducer. SP=symphysis pubis, U=urethra, V=vagina.



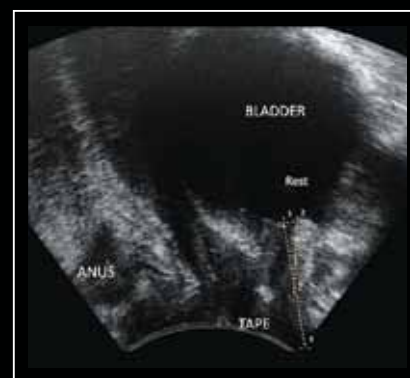
Sagittal section. Measurements reflect position of the pelvic floor organs at rest (left image) and during Valsalva maneuver: anorectal angle (red), retrovesical angle (yellow), bladder neck-symphysis pubis distance (BSD) (green).



Sagittal section during Valsalva maneuver. Cystocele is visualized.



Sagittal section. Rectocele visualized during Valsalva maneuver.

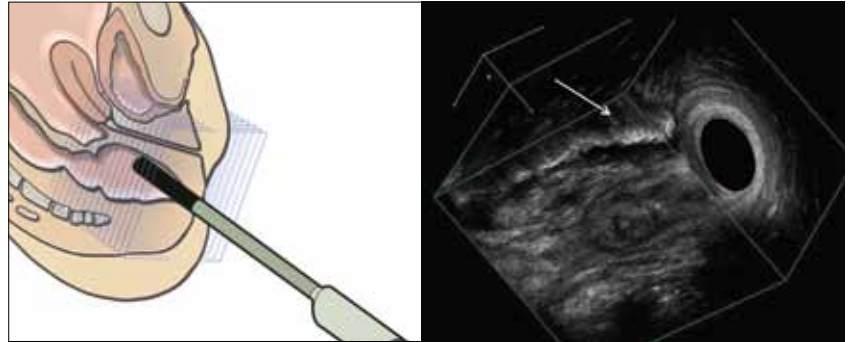


Sagittal section showing pelvic organs. Tape is clearly visualized.

# High Resolution Endoanal and Endovaginal 3D

Rotate and cut through the high resolution 3D data cube to see areas of interest in the best possible planes and follow the path of abnormalities. Make reproducible measurements.<sup>1</sup>

The 2052 endocavity transducer with built-in, high resolution 3D, has a rotating crystal that sweeps out a 360° ultrasound image. The crystal moves back within the probe to acquire a series of parallel images that create the 3D data cube, as indicated in the drawing. Acquisition is automatic, and no moving parts touch the patient.



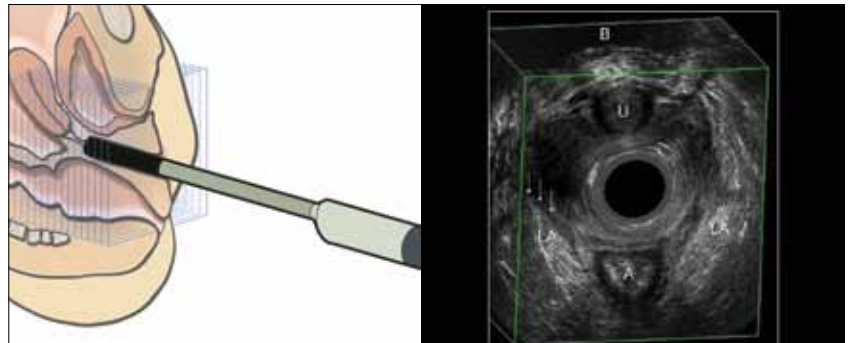
Endoanal ultrasound after H2O2 injection-fistulography. Fistulous tract (arrow) is better seen in tilted sagittal section.

## Endoanal 3D

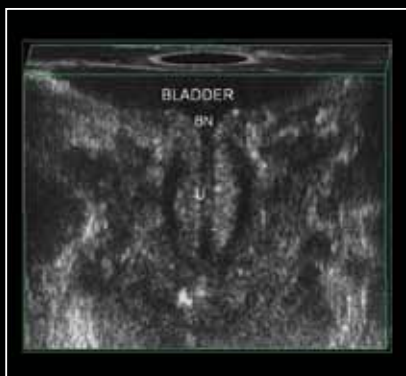- Evaluate the structural integrity of the anal canal, including abscesses, fistulas and sphincter tears
- Follow fistula paths in precise detail
- Visualize anal tumors
- Detect mucosal rectal prolapse

## Endovaginal 3D

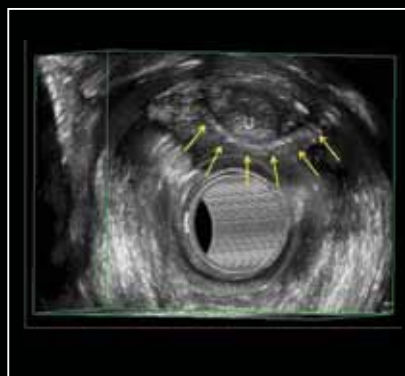
- Assess pelvic floor asymmetry
- Measure the levator hiatus
- Assess perineal muscles
- Visualize levator ani muscle and attachment to inferior pubic rami



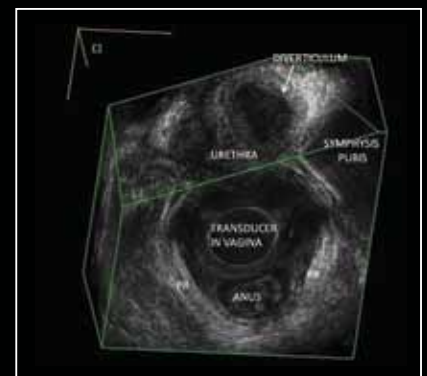
Endovaginal ultrasound. Levator ani defect seen on the right side (arrows). A=anus, B=bladder, LA=levator ani, U=urethra.



Coronal view of the urethra. BN=bladder neck, U=urethral lumen.



Axial view of the urethra. Tape is clearly visualized (arrows). U=urethra.



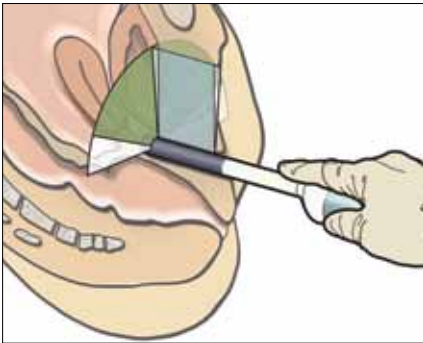
Endovaginal ultrasound. Urethral diverticula clearly visualized in a tilted oblique plane. PR=puborectalis muscle.

<sup>1</sup> Santoro GA, Wieczorek AP, Shobeiri SA et al. Interobserver and interdisciplinary reproducibility of 3D endovaginal ultrasound assessment of pelvic floor anatomy. *Int Urogynecol J Pelvic Floor Dysfunct* 2011;22(1):53-9.

# Dynamic Endovaginal Imaging

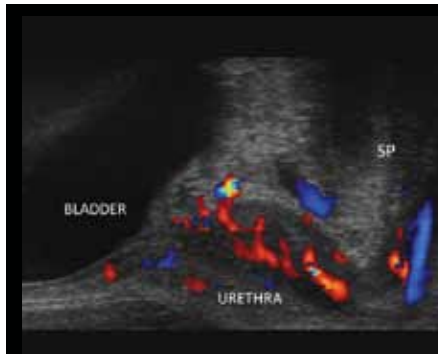Image the anterior and posterior compartments with the high resolution biplane 8848 transducer to see anatomical, vascular and functional details. With an external 3D mover, you can also obtain high resolution 3D data cubes.

The two arrays in the 8848 biplane transducer let you see vascularity in detail in both sagittal and transverse image planes. For example, viewing the transverse image while you retract the transducer lets you visualize flow along the length of the urethra.

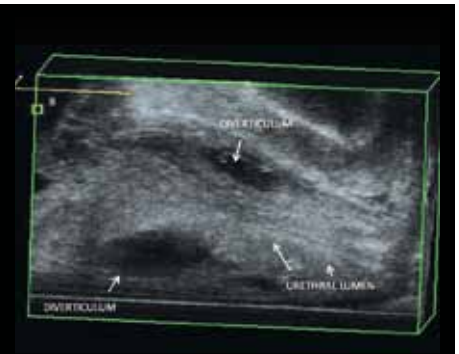


## Anterior Compartment

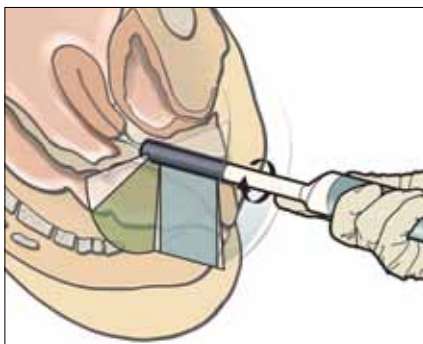
- Visualize bladder neck, urethra and other structures
- Assess intussusception, enteroceles and rectoceles
- View tapes and meshes



Urethral vascularity (sagittal section of the urethra). SP=symphysis pubis.

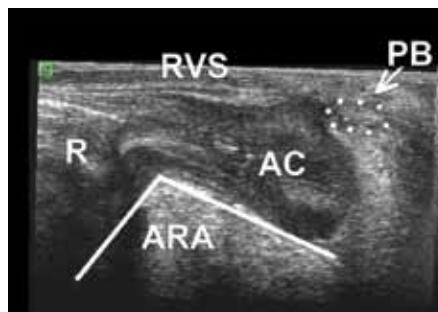

Sagittal section of the urethra, revealing urethral diverticula.

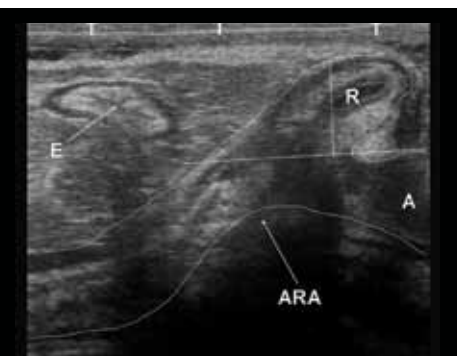

## Posterior Compartment

- Visualize hemorrhoids and the perineal body
- Measure anorectal angle
- Evaluate RVS (rectovaginal septum) integrity



Sagittal section of the posterior compartment. AC=anal canal, ARA=anorectal angle, PB=perineal body, R=rectum, RVS=rectovaginal space.



Sagittal section of the posterior compartment. A=anus, ARA=anorectal angle, E=enterocele, R=rectum.

# Unique High Resolution Color and 3D Imaging

Visualize blood flow with color Doppler and acquire a 3D data cube for detailed examination and measurements – all with the same high resolution transducer.

The revolutionary 8838 endocavity transducer, with both sensitive color Doppler and built-in 3D, is the newest addition to our unique high resolution pelvic floor ultrasound solution. The linear sagittal array rotates automatically to acquire the 3D data cube from a fan of separate images. The transducer's small diameter minimizes patient discomfort, and no moving parts touch the patient.

## 2D and Color Doppler High Resolution Imaging

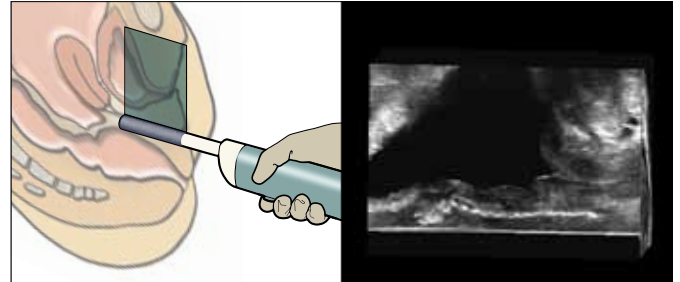
- See motion and flow (color) with superb sensitivity
- Visualize anatomical, vascular and functional details
- Explore the integrity and position of tapes and meshes

## Endoanal 3D

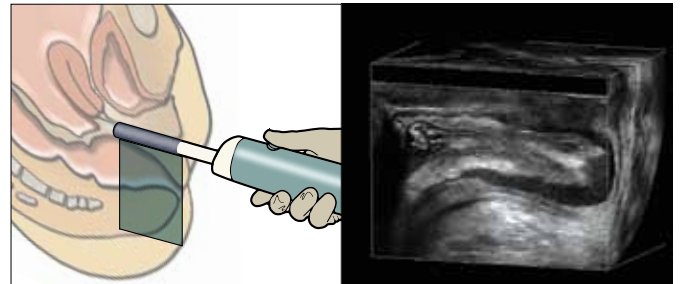
- Perform a complete 360° high resolution endoanal 3D study
- Evaluate anal canal integrity
- Assess levator ani integrity
- Evaluate fistula tracts and abscesses
- Detect rectal prolapse and obstruction

## Endovaginal 3D

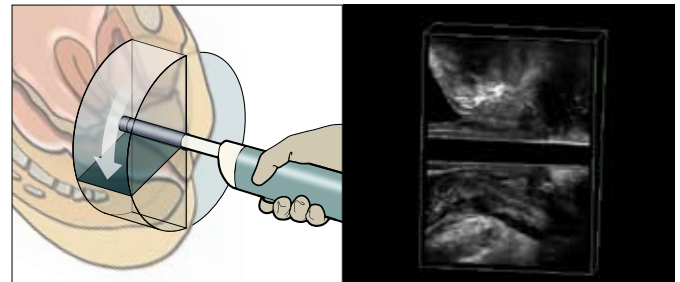
- Perform a high resolution endovaginal 3D study of the complete pelvic floor
- Obtain high resolution images of the rectovaginal space



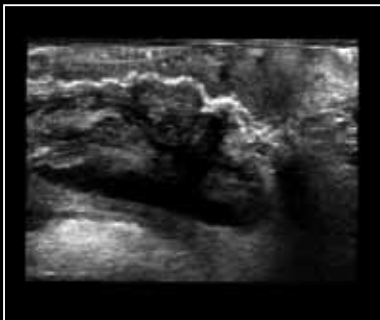
Midsagittal view (12 MHz). Bladder and urethra are clearly visualized, and below them, an anterior mesh.



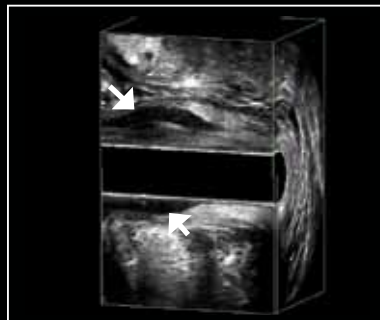Sagittal section from a 3D image of the posterior compartment. Interior lumen of the anal canal and puborectalis clearly visualized.



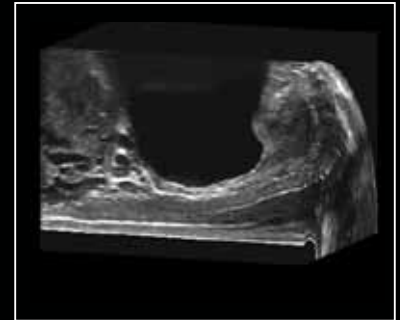
Midsagittal section from an endovaginal 360° image (12 MHz). At the top, the anterior compartment with the urethra clearly visualized. Below this, the rectovaginal space, anal canal and puborectalis.



Sagittal endovaginal view of the posterior compartment (12 MHz). Posterior mesh clearly visualized between vagina and anal canal.



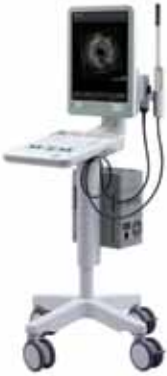Midsagittal section from an endoanal 3D image of the anal canal (12 MHz). Note very clear visualization of internal sphincter.



Sagittal view from an endovaginal image of anterior compartment. Structures surrounding urethra are seen to the right, bladder in the center. Below the bladder, structures between vagina and bladder are seen with very fine details.

# Acoustic and Clinical Innovators for over 30 years

Recognized as a global leader in the development of ultrasound systems designed for urology, surgery and pelvic floor, Analogic's BK Medical offers a versatile range of state-of-the-art imaging systems and dedicated transducers to help enhance diagnostic confidence.



## flexFocus 800 and flexFocus 500

Award-winning, extremely mobile fully featured systems, combining Quantum Technology™ with an intuitive user interface and customizable settings. When coupled with the BK Power Pack, ensures plug-free imaging for up to 4 hours. The premium performance flex Focus™ 800 also offers a choice of interfaces, including a touch screen and remote control.





## UltraView 800

A fully featured ultrasound system incorporating Quantum Technology, providing high resolution images designed to meet demanding clinical challenges. The system is a work-horse solution for university centers as well as private clinics.



## Pelvic Floor Transducers

We lead the way in pelvic floor transducers, with the world's best high resolution 3D image quality and built-in 3D movers, so no moving parts touch the patient.

Curved Array	Anorectal 3D	Endocavity Biplane	3DART™
<b>8802</b>	<b>2052</b>	<b>8848</b>	<b>8838**</b>
6-3 MHz	16-6 MHz	12-4 MHz	12-4 MHz
			

\*\* Not licensed by Health Canada for use with the flex Focus 1202

### Sales Offices

**B-K Medical Benelux NV/SA**  
 Generaal de Wittelaan 19/B  
 2800 Mechelen, Belgium  
 T: +32 1528 0600  
 F: +32 1529 1025  
 Email: info@be.bkmed.com

**B-K Medical Medizinische Systeme GmbH**  
 Paskalkehe 13  
 25451 Quickborn, Germany  
 T: +49 4106 99 55-0  
 F: +49 4106 99 55-99  
 Email: info@de.bkmed.com

**B-K Medicele S.r.l.**  
 Via Tulipani, 1  
 20090 Pieve Emanuele MI, Italy  
 T: +39 02 90 78 13 47  
 F: +39 02 90 78 19 05  
 Email: info@it.bkmed.com

**B-K Medical AB**  
 Mänskärsvägen 9  
 141 75 Kungens Kurva, Sweden  
 T: +46 8-744 02 11  
 F: +46 8-744 02 12  
 Email: info@se.bkmed.com

**B-K Medical (UK)**  
 Unit 20a/20b Basepoint Business & Innovation Centre 110  
 Butterfield, Great Marlings, Luton Bedfordshire LU2 8DL  
 United Kingdom  
 T: +44 1628 825-770  
 F: +44 1628 826-970  
 Email: info@uk.bkmed.com

 BK Medical ApS, Mileparken 34, 2730 Herlev, Denmark. Tel.: +45 44528100 Fax: +45 44528199 Email: info@bkmed.dk

### Innovative Solutions for Life

Analogic Corporation creates innovative technology to improve the health and enhance the safety of people around the world. We are committed to providing ultrasound solutions under the BK Medical brand name that advance medicine and save lives.



**Analogic Corporation - Headquarters USA**  
 8 Centennial Drive, Peabody, MA 01960  
 T: 978-326-4000  
 analogic.com

**BK Medical - Sales and Service USA**  
 8 Centennial Drive, Peabody, MA 01960  
 T: 978-326-1300  
 bkmed.com

**BK Medical - Europe and Rest of World**  
 Mileparken 34, 2730, Herlev, Denmark  
 T: +45 4452 8100  
 F: +45 4452 8199  
 bkmed.com

The name Analogic is a registered trademark of Analogic Corporation. The globe logo is a trademark of Analogic Corporation.